

# EFFECTIVE MANAGEMENT OF A NON-HEALING WOUND POST-MOHS SURGERY USING A NOVEL SELF-ASSEMBLING PEPTIDE-BASED ADVANCED WOUND DRESSING

Laura Pfendler PT, DPT

Director, Advanced Wound Care,  
Kapp Plastic Surgery & Wound Care

Kalpana Kamath PhD

Consultant, Arch Therapeutics, Inc.

Daniel C Wadsworth Jr

VP Dermal Sciences, Arch Therapeutics, Inc.

Daniel Kapp MD

Chief of Plastic Surgery & Wound Care, Palm Beach  
Gardens Medical Center

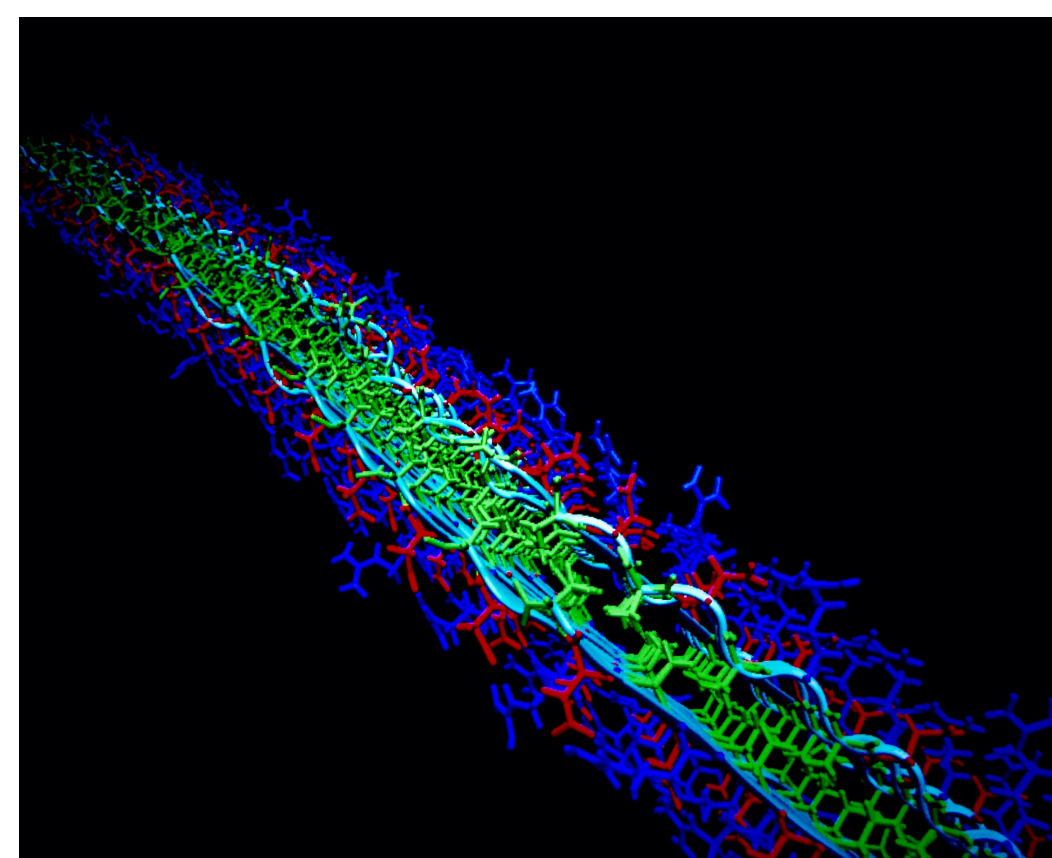
## Background

Repair of lower extremity wounds after Mohs micrographic surgery can be challenging due to a high propensity for complications and a painful, protracted healing course. Among the few options that have been investigated for their management include the use of partial- or full-thickness skin grafts and flaps<sup>1</sup>. This case examined the use of a novel and proprietary self-assembling peptide-based product called, AC5 Advanced Wound System<sup>2</sup> (“AC5”), to treat a non-healing surgical wound persisting two months post-Mohs surgery.

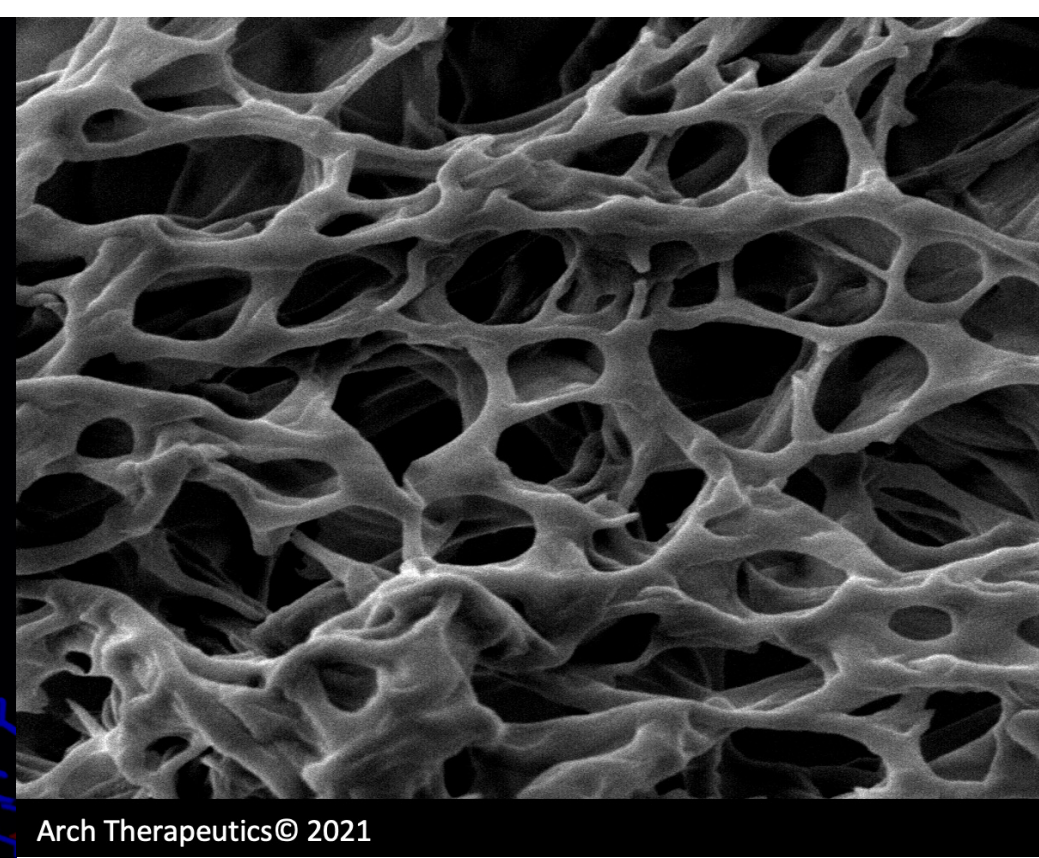
## Technology: AC5 Advanced Wound System<sup>2</sup>

AC5 Advanced Wound System (AC5) is a novel dressing. The mechanism of action derives from the physiochemical properties of its synthetic peptide. Upon exposure to ions in wounds, peptide units self-assemble into higher ordered nanofibrils and nanofibers before culminating in an entangled network. An extracellular matrix-like structure that contours to the macro and micro architecture of the wound milieu is formed. The network resembles that of collagen and provides a scaffold, enabling cell migration and proliferation as well as repair of damaged tissue.

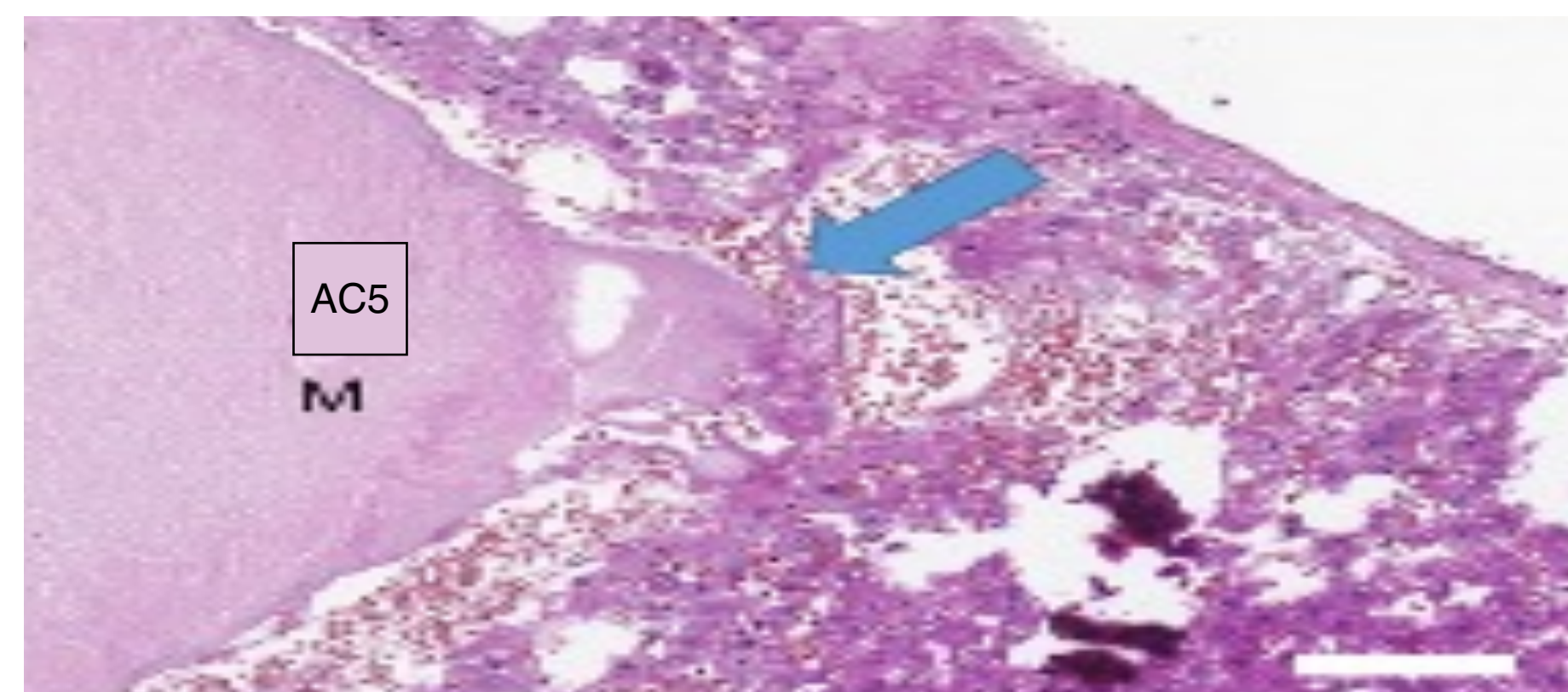
### AC5 Nanofibril<sup>3</sup>



### Electron Micrograph of AC5<sup>3</sup>



### Contiguous Cohesive AC5 Nanofiber Network<sup>3</sup>



## Case Study

A 51-year-old male patient presented with a non-healing surgical wound of the pre-tibial, right lower leg. The patient underwent Mohs surgery for squamous cell carcinoma nine weeks prior to presenting to this clinic. The patient has a history of chronic deep vein thrombosis causing a right pulmonary artery chronic thrombus and idiopathic mediastinal fibrosis, as well as hypertension and dyspnea. Previous wound-care treatment included use of various topical antibiotics and non-adhesive pads.

## Methods: AC5 Preparation

Using an 18-gauge needle attached to a 3ml syringe, 1.5ml of sterile water was transferred to the vial containing the lyophilized peptide. Leaving the needle in place, this vial was then gently shaken until the peptide was completely dissolved in the sterile water. The solution was then drawn directly into the syringe and the needle removed from the vial. An 18-gauge blunt applicator was attached the syringe. A small amount of the solution was expressed to prime the blunt applicator.

## Methods: Procedure & Application

Treatment with AC5 was initiated immediately after excisional debridement. The wound was dressed with Xeroform and Unna Boot compression was applied. This regimen was repeated weekly for a total of four applications.

## Results

Upon admission, the wound had a moderate amount of slough and measured 2.6 cm<sup>2</sup>. This regimen was repeated weekly for a total of four applications. During the course of the treatment, granulation tissue increased, and the wound surface area progressively decreased 90% by the final application (Figure 1). The wound had completely healed by the final follow-up visit at week six.

## References

- <sup>1</sup> Oganessian, G. et al, Efficacy and complication rates of full-thickness skin graft repair of lower extremity wounds after Mohs microscopic surgery. Dermatologic Surgery, 39, 1334-1339, 2013
- <sup>2</sup> AC5® Advanced Wound System, Arch Therapeutics, Inc., Framingham, MA
- <sup>3</sup> © 2019 Arch Therapeutics, All Rights Reserved; Data on File
- <sup>4</sup> © 2020 Arch Therapeutics, All Rights Reserved; Data on File

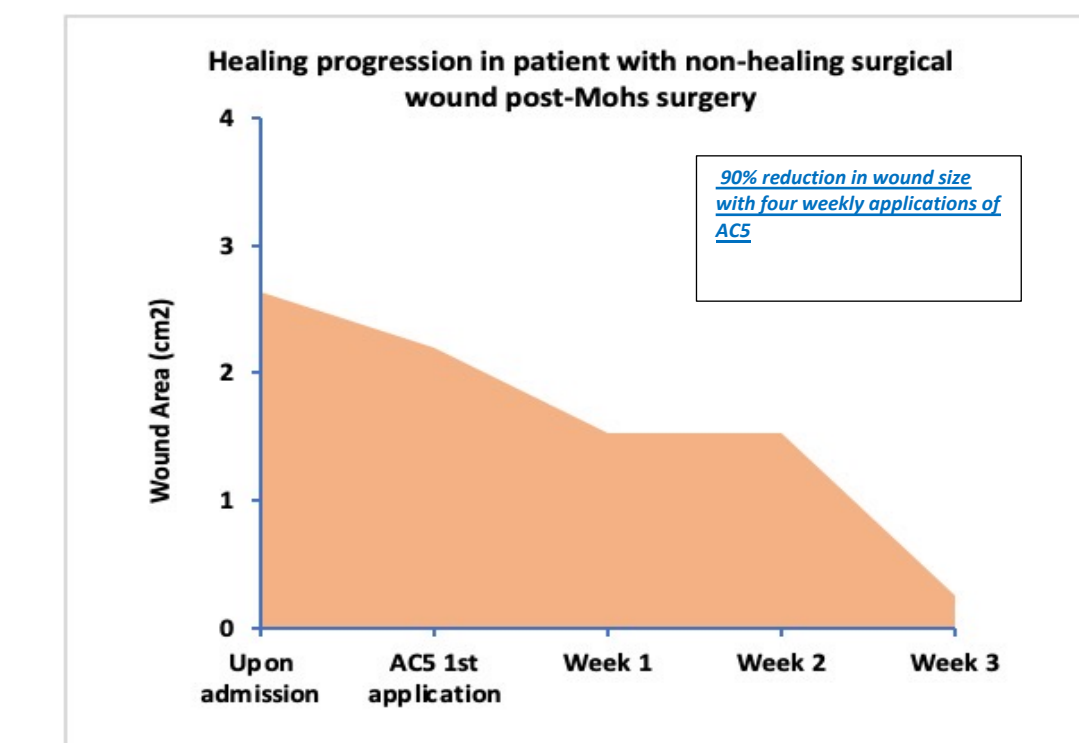
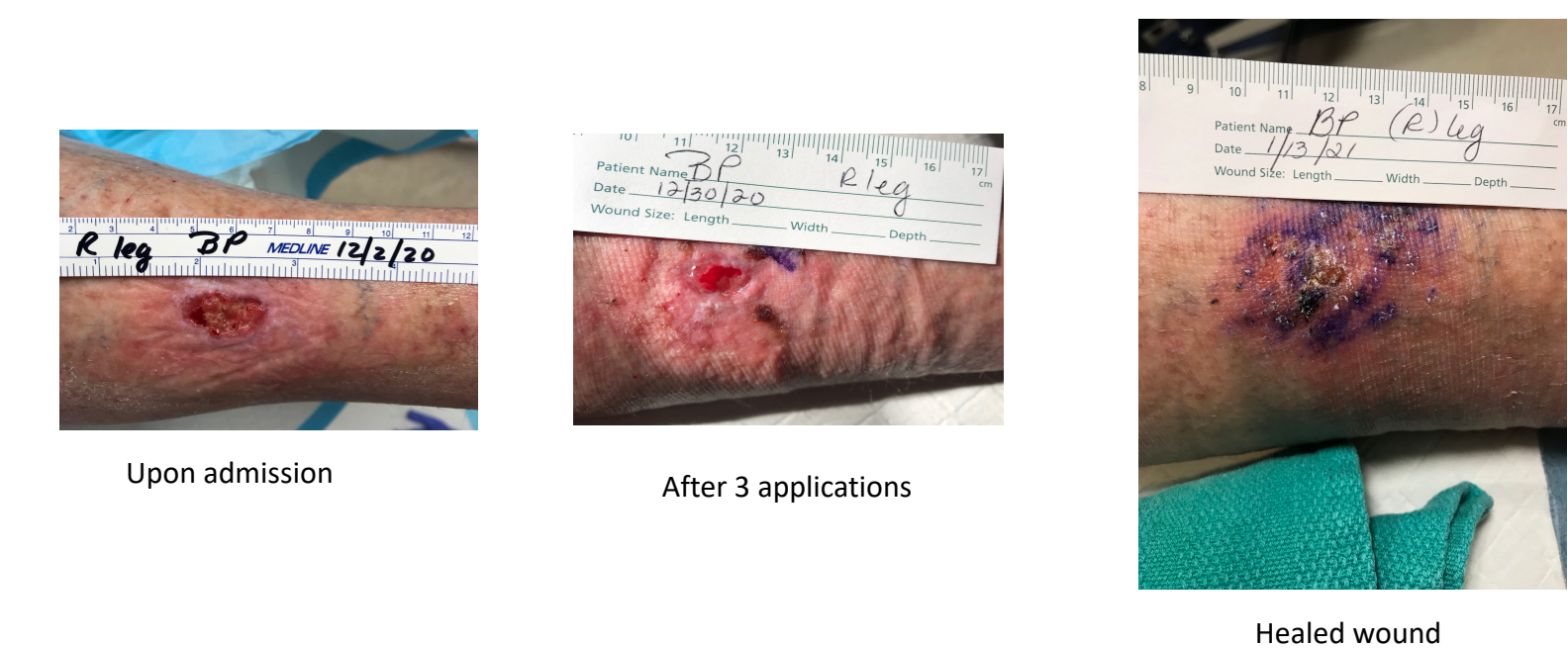

Figure 1: Wound healing progression, as demonstrated by 90% reduction in wound size with four weekly applications of AC5



## Conclusions

Concomitant use of excisional debridement and treatment with AC5 markedly accelerated healing of this stalled wound, which had failed two months of standard therapy. The effect of AC5 may be attributed to the contiguous barrier it creates along the wound surface after debridement, in addition to its ability to promote cell adhesion, migration, and proliferation, which are essential for wound healing.

## Disclosures

AC5 is a registered trademark of Arch Therapeutics, Inc, which owns commercial rights to AC5. Dr. Kapp is a clinical advisor to Arch Therapeutics.